



Subterranean specialization of the ear morphology in Chinese zokor *Eospalax fontanieri*: Indication of an acoustic fovea

Lucie Pleštilová¹, Ema Hrouzková¹, Hynek Burda^{1,2}, Limin Hua³, Radim Šumbera¹

¹ Department of Zoology, Faculty of Science, University of South Bohemia, České Budějovice 39005, Czech Republic; ² Department of General Zoology, Faculty of Biology, University of Duisburg-Essen, D-47074 Essen, Germany; ³ College of Forestry and Landscape Architecture, Nanjing Agricultural University, 210095 Nanjing, China

Hearing plays an important role in communication and sensing of danger in subterranean mammals. Burrows are characterized by specific acoustics with low frequencies of about 0.4 - 1 kHz being transmitted better than lower and higher frequencies (Heth et al. 1986, Lange et al. 2007). Subterranean rodents display hearing and vocalization tuned to this frequency range. Their pinnae are missing or reduced, the meatus is narrow, the middle ear displays convergent morphological features typical for mammals with hearing tuned to low frequencies and reduced hearing sensitivity (Burda et al. 1992). The inner ear is characterized by a high, coiled cochlea, long and wide basilar membrane, high number of hair cells in the apical region and a high ratio between outer and inner hair cells (Müller et al. 1989, Begall and Burda 2006, Schleich et al. 2006). In the African mole-rat *Fukomys anselli*, a unique inner ear specialization, the so called acoustic fovea, was described, a region on the basilar membrane where the frequencies with biological significance are overrepresented (Müller et al. 1992). Similar specialization was noticed also in blind mole rat *Spalax ehrenbergi* (Bruns et al. 1988).

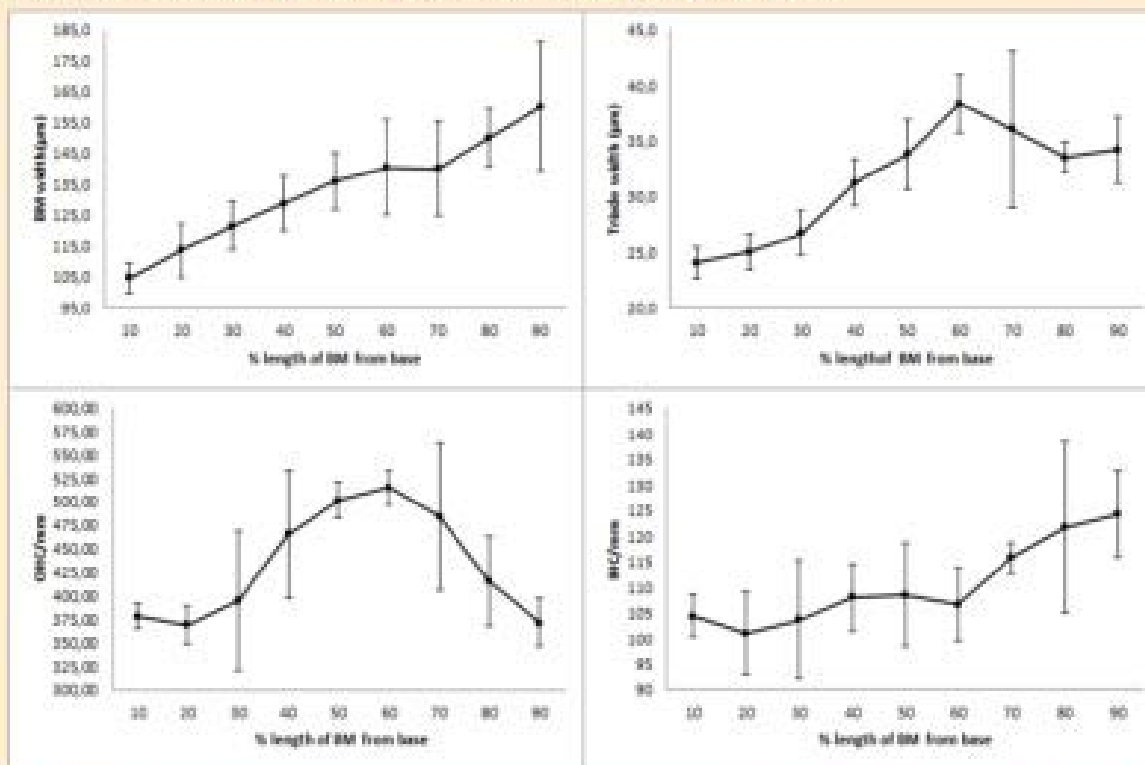


Figure 1. The width of the basilar membrane and the OHC row and the density of OHC and IHC along the organ of Corti, the change of the slope is approximately 60 percent from base is apparent in all cases.

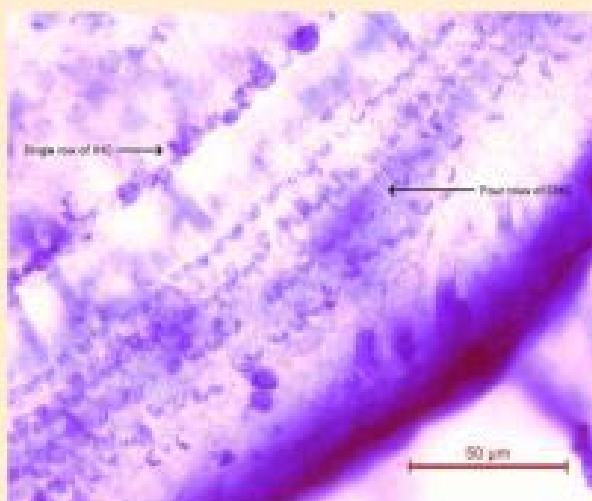


Figure 2. The section of the Corti organ with four rows of OHC.

Conclusions:

The inner ear of the Gansu zokor shown morphological traits common for other subterranean species (a coiled cochlea and a wide basilar membrane). The width of the basilar membrane remained almost constant between 60 and 70% of its length, suggesting thus the existence of an acoustic fovea. The density of IHC was the highest in the apical part of Corti organ, while the highest density of OHC occurred in about the middle of the spiral, thanks to the existence of four rows. This segment contains a high number of hair cells (compared to *S. ehrenbergi* and *F. anselli*, fig. 3), a trait that can be interpreted as the frequency area of the best hearing sensitivity.

Acknowledgements: This study was supported by the grant agency of University of South Bohemia 163-045/2015/P and the Department of Zoology, UZB.

References: Segal S. & Burda H. (2006): Acoustic communication and burrow acoustics are reflected in the ear morphology of the caecum (Dipodomys deserti, Ochrotaxidae), a vocal burrowing rodent. *J. Mammal.* 87: 382-390. • Burda H., Müller H., Heth M., Heth G. & Nevo E. (1988): Inner ear morphology and physiological acoustics of the subterranean mole rat, *Spermophilus roborator*, hearing for 30 kHz. • Burda H., Müller H. & Nevo E. (1989): Cochlea in subterranean mole rat, *Spermophilus roborator*. *J. Morphol.* 195: 249-260. • Heth G., Ehrenberg S. & Nevo E. (1986): Adaptive optimal sound to sound communication in tunnels of subterranean mole-rat (*Spermophilus roborator*). *Physiological Zoology* 59: 1287-1291. • Wang J., Burda H., Wagner K., Demmel P., Segal S. & Burda H. (2007): Living in a "Mafesque" burrow: acoustic communication and hearing in subterranean mole-rat, *Spermophilus roborator*. *Nat. Commun.* 8: 1-5. • Müller H., Louie S., Burda H. & Nevo E. (1992): Structure and function of the cochlea in the African mole rat (*Dipodomys deserti*): evidence for a low frequency acoustic fovea. *J. Comp. Physiol.* 171: 467-475. • Schleich CE, Segal S & Burda H. (2006): Molecular-functional parameters of the inner ear in *Dipodomys deserti* (Dipodomysidae, Rodentia). *PLoS One* 1: 264-272.

Materials and methods:

Six adult (3M, 3F) zokors (*E. fontanieri*) captured in Jiangsu Grassland Station (Gansu, China) were examined. The specimens were fixed in formalin, the cochleae were prepared and the Corti organ was stained with toluidine blue and Ehrlich's hematoxylin as described in Burda et al. (1988). The basilar membrane was extracted and mounted in glycerin on a microscope slide. The total length of the basilar membrane was measured and divided into ten equal segments. The width of the organ of Corti, radial width of three rows of outer hair cells (OHC row) and density of outer and inner hair cells was measured in each segment. All measurements were taken under magnification $\times 400$.

Results:

The cochlea had 3.5 turns, the basilar membrane was 13.15 (± 1.13) mm long. The width of the organ of Corti varied from 140 (± 21) μ m in the apex to 104.5 (± 5.1) μ m in the base. Hair cells were arranged in a regular pattern with one row of inner hair cells (IHC) and three or four rows of outer hair cells (OHC). The fourth OHC row occurred at 20 - 50 percent of the length of the Corti organ from the base, mostly in the middle of the cochlear spiral (fig. 2). The mean density of IHC was 110.38 (± 8.22) cells per mm, the mean density of OHC was 432.97 (± 58.95) per mm (fig. 1).

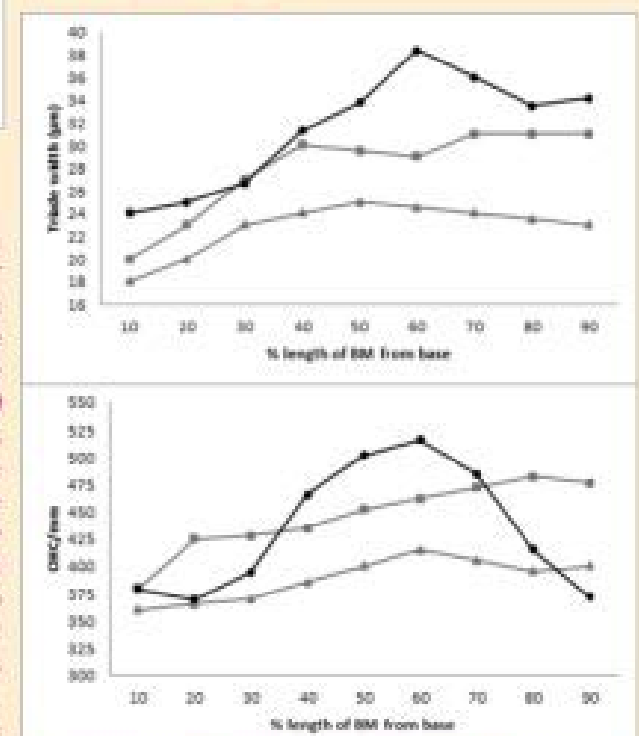


Figure 3. The width of three (or four) rows of OHC and their density per mm in *E. fontanieri* (black circles), *S. ehrenbergi* (grey triangles), and *F. anselli* (grey squares). The acoustic fovea is around 60% BM length in *E. fontanieri*, in the other species it is in whole second half of BM.